

DOI: 10.5281/zenodo. 24261114

A CASE REPORT ON IMPLANT THERAPY FOR A PATIENT WITH SUBSTANTIAL CONDENSING OSTEITIS

Asem Ibrahim AlKhodairi^{1*}, Mohammad Meish AlMohammadi² and Mohammed Khalid AlMoharib³

¹Department of Restorative Dentistry, Hail Dental Center - Ministry of Health. Email: iDr.Asem@Gmail.com

²Department of Restorative Dentistry, Prince Abdulrahman Advanced Dental Institute, Armed Forces Health Services, Riyadh.

³Department of Restorative Dentistry, King Fahad Medical City - Ministry of Health. Saudi Arabia - Riyadh.

Received: 04/04/2026
Accepted: 20/05/2026

Corresponding Author: Asem Ibrahim AlKhodairi
(iDr.Asem@Gmail.com)

ABSTRACT

Condensing osteitis is a maxillomandibular disease that often develops as a result of the body's attempt to protect itself from infection. It is usually found at the apex of the root of a prolonged, unresolved infection or in teeth that have received incorrect endodontic treatment. The bone marrow demonstrates extensive trabeculae development. This presents as a hyperdense lesion near the damaged tooth's apex. Condensing osteitis must be detected via adequate clinical and radiological screening. A 26-year-old male patient described in this case report presented to the clinic with a broken 36. Condensing osteitis was diagnosed through radiographic and clinical evaluation. The case was managed by extraction of tooth 36, followed by implant-supported rehabilitation after three months. A healing period of five months was allowed to promote osseointegration. No implant-related complications or pathological changes were observed during the three-year follow-up period.

KEYWORDS: Condensing Osteitis, Focal Sclerosing Osteitis, Dental Implant.

1. CASE SUMMARY

A 26-year-old male came to the department with a one-week-old fracture in the bottom rear portion of his left tooth. No discomfort was noted. The patient disclosed a history of restoration in the area of pain following root canal therapy (RCT) two years ago. The patient also acknowledged a history of food Impaction in the past 12 months. The patient provided no relevant medical background information. There were no edema or any odd findings identified during the extraoral examination. In conjunction with the crown fracture, an intraoral examination revealed a fragmented amalgam repair on the mesiocoronal side of 36. Tooth movement was nonexistent. Secondary caries occurs in the distal region of 36, beneath the crown. Both the buccal and lingual connected gingiva were not swollen. There was no vestibular obliteration.

The orthopantomogram (OPG) that was proposed to the patient showed hyperdensity in the coronal area of 36, indicating a crown. The mesial and distal roots showed radiopacities that led to the incorrect conclusion that Gutta Percha points existed. A little horizontal bone loss was seen in 36 cases. Hypodensity was identified in the furcation region. With root resorption, there was a hypodensity of about 2×1 mm at the apex of the mesial root of 36. A separate hyperdensity of around 3×2 mm was seen beneath the hypodensity, which was not related to the mandibular canal. There was no lamina dura visible. During distal root resorption, a hypodensity of 36 is found near the apex of the root. No negative impact on surrounding structures was seen. On the indicated CBCT, a clear hyperdense lesion with no radio-lucent rimming was found near the mesial root of 36. The OPG's observations and the CBCT's were comparable. [As shown in Figure 1A] Condensing osteitis was

diagnosed based on radiographic results and clinical correlation. Cementoblastoma and cemento-osseous dysplasia were distinct. Condensing osteitis appears as a hyperdense region with no discernible hypodense halo, but a cementoblastoma appears as a hyperdense mass with a distinct hypodense boundary encircling it. Condensing osteitis is characterized by a specific hyperdense zone enclosing the tooth root, which is typically caused by a greater periodontal ligament gap, whereas COD may have a more widespread hyperdense pattern with probable lamina dura damage.

Condensing osteitis was eventually verified following extensive radiographic examination, a thorough history, and clinical coherence. The diagnosis was explained to the patient, and extraction of tooth 36 was recommended. The patient was advised that an implant prosthesis will be utilized to replace the missing teeth. Tooth 36 was extracted atraumatically because the patient had no significant medical history. [As shown in Figures 1b, 1c, and 1d] A delayed implant placement protocol was selected for three months to minimize the risk of infection and allow adequate healing prior to implant placement.

After three months, a Straumann 4.1×10 mm implant was placed, followed by a five-month healing period. A healing abutment was also placed to support proper soft tissue healing and implant integration. [as revealed in figures 2a–2d] Following noteworthy osseointegration, a screw-retained zirconia crown was placed over the implant prosthesis. At the three-year follow-up, the implant remained clinically stable with no signs of infection, complications, or adverse pathological changes. [as revealed in figures 3a–3d] The patient continues to undergo periodic clinical and radiographic follow-up.

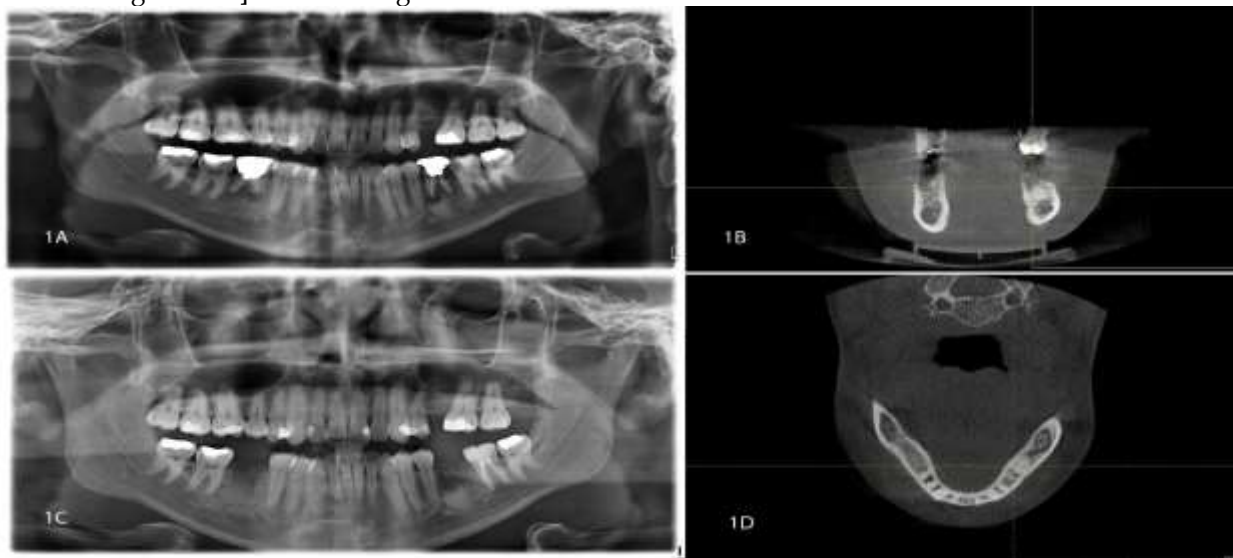


Figure 1

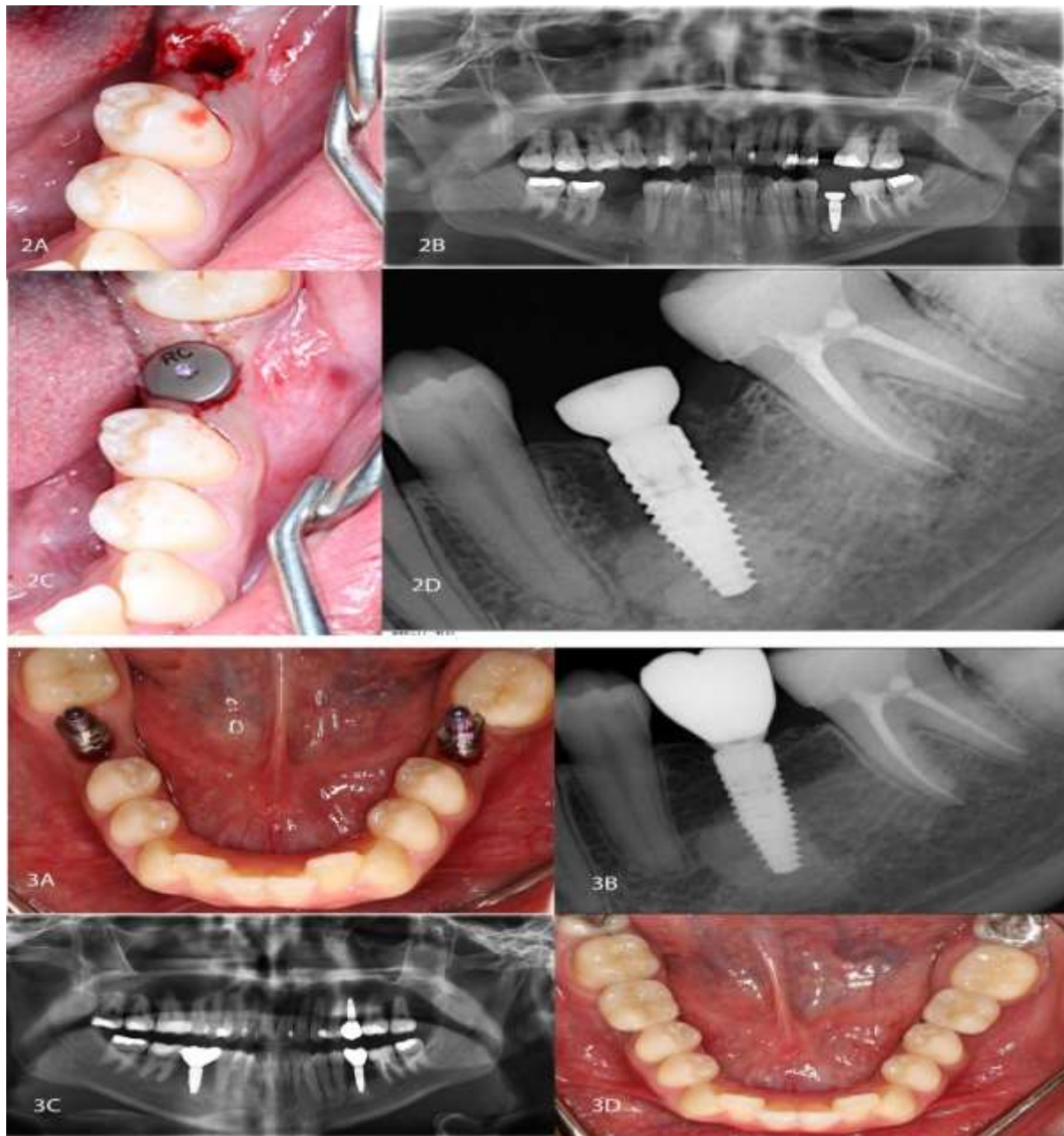


Figure 2

2. DISCUSSION

Chronic focal sclerosing osteitis refers to a hyperdense, localized jaw lesion that is asymptomatic.[1] A mild pulp infection causes bone growth. Chronic focal sclerosing osteitis is also called condensing or sclerosing osteitis.[3] The root canal is agitated marginally and persistently by low-virulence bacteria in the residual necrotic pulp, causing a bone reflex.[4] They are often discovered during routine dental radiograph examinations and are commonly encountered in the jaw region. Bone formation, caused by a small infection of the pulp tissues, is a distinguishing aspect of the sickness.

The body's defensive response against the illness causes the affected tooth to become infected, which is usually associated with a prolonged pulpal infection.[6] When characterizing a condensing osteitis lesion, it is important to consider idiopathic sclerosis, a periapical hyperdense lesion.[7] Because of the multiple cavities and large fillings that are sensitive to pulpitis and pulp necrosis, the first molar in the lower jaw is more likely to develop condensing osteitis. The second molar is located in the lower jaw.[8] The condition of the affected tooth dictates how condensed osteitis is treated.

In the current case study, tooth number 36 had

both root resorption and unsatisfactory endodontic treatment, therefore Extraction was the only realistic option. As a result, we planned to remove 36 teeth and replace them with dental implants. We delayed implant insertion for three months after extraction in order to limit the risk of infection. However, if the lesion was caused by insufficient root canal treatment, it will not disappear.[1] Condensing osteitis generally has a favorable prognosis because it can be efficiently treated with the proper endodontic procedures. Inflammation and complete regression of the sclerotic bone are both possible healing outcomes.

In contrast, if the lesion is more widespread, the recommended therapy is often the extraction of the

tooth and complete removal of the pathologically changed bone.[2] In this case, extraction and substitution were the only options due to a condensing osteitis lesion in a long-standing carious tooth that had not received proper RCT treatment. After three years of follow-up, the patient was clinically asymptomatic and is still being examined.

3. CONCLUSION

In condensing osteitis, Frequent radiographic examination is crucial for detecting such lesions, and when therapy is carried out as intended, as we did in this case, the prognosis is often favorable.

REFERENCES

- Dukic W, Filipovic-Zore I, Bago I. Condensing osteitis-case report. *Acta Stomatol Croat.* 2006; 40:182-8.
- Elfenbaum A. Condensing osteitis in the dental x-ray. *Dent Dig.* 1967; 73:554-558.
- Gupta S, Dutta S, Baby A, Langthasa M. Condensing Osteitis - A Review and Case Report. *Asian Pac. J. HealthSci.* 2023; 10(2):69-72.
- Holly D, Jurkovic R, Mracna J. Condensing osteitis in oral region. *Bratisl Lek Listy.* 2009; 110:713-5.
- Kawai T, Hirakuma H, Murakami S. Radiographic investigation of idiopathic osteosclerosis of the jaws in Japanese dental outpatients. *Oral Surg Oral Med Oral Pathol.* 1992; 74:237-242.
- Reema A Sharaf. Clinical Management of Condensing Osteitis: A Case Report. *J Res Med Dent Sci.* 2025; 13(1):1-3.
- Williams TP, Brooks SL. A longitudinal study of idiopathic osteosclerosis and condensing osteitis. *Dentomaxillofac Radiol.* 1998; 27:275-8.
- Yeh HW, Chen CY, Chen PH. Frequency and distribution of mandibular condensing osteitis lesions in a Taiwanese population. *J Dent Sci* 2015; 10:291-5.